# Fetal Medicine Foundation
# Assessment of the Ductus Venosus

- The gestational period must be 11 to 13 weeks and 6 days.
- The examination should be undertaken during fetal quiescence.
- The magnification of the image should be such that the fetal thorax and abdomen occupy the whole image.
- A ventral right para-sagittal view of the fetal trunk should be obtained and colour flow mapping should be undertaken to demonstrate the umbilical vein, ductus venosus and fetal heart.
- The pulsed Doppler sample volume should be small (0.5 mm) to avoid contamination from the adjacent veins, and it should be placed in the yellowish aliasing area of the ductus venosus.
- The insonation angle should be less than 30 degrees in respect to the longitudinal axis of the ductus venosus.
- The filter should be set at a low frequency (50-70 Hz) so that the a-wave is not obscured.
- The sweep speed should be high (2-3 cm/s) so that the waveforms are spread allowing better assessment of the a-wave.

When these criteria are satisfied, it is possible to assess the a-wave and determine qualitatively whether the flow is positive, absent or reversed.

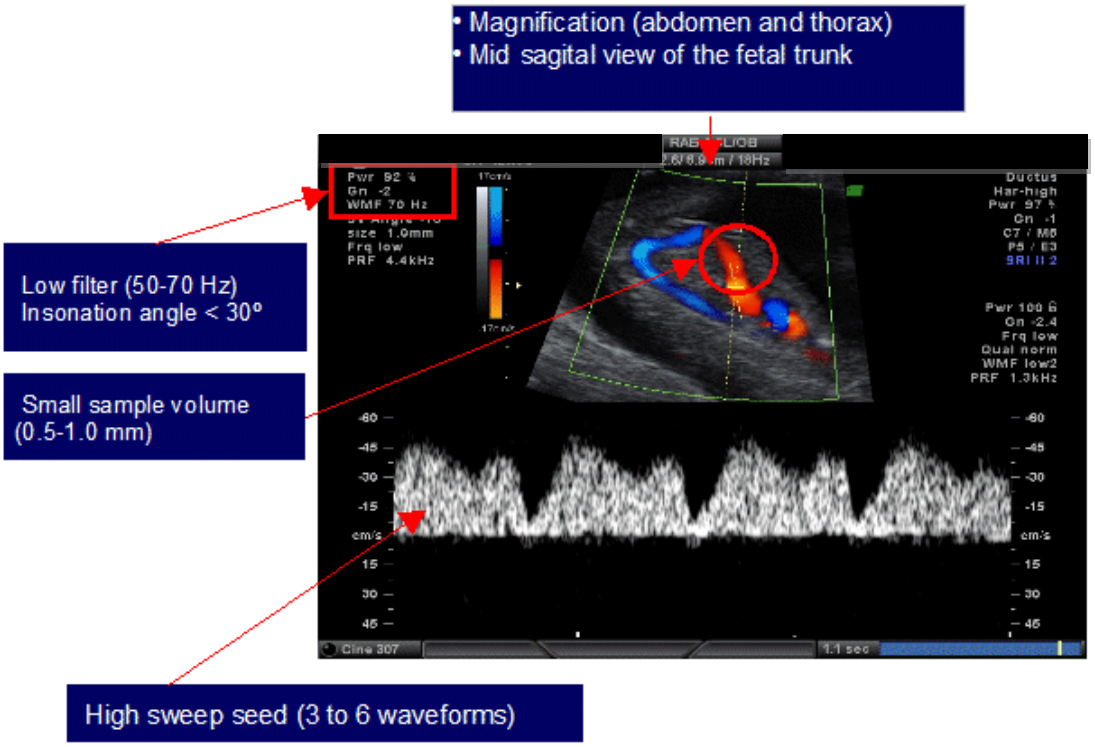


**Requirements for accreditation in first trimester assessment of the ductus venosus flow are:**

- FMF accreditation in the measurement of nuchal translucency.
- Attendance of the internet based course on the 11-13 weeks scan.
- Submission of 3 images demonstrating the ductus venosus waveform.